

# METAPLASTIC BREAST CARCINOMA IN A PREGNANT WOMAN: CASE REPORT

## Carcinoma metaplásico da mama em uma gestante: relato de caso

Jocela Cristina dos Santos<sup>1</sup>, Andrea Tatiane Oliveira da Silva<sup>2</sup>, Marta Maria Vasconcelos de Araújo<sup>3</sup>, Caroline Carvalho Ferro<sup>3</sup>, Raiana Santos Lins<sup>4\*</sup>

### ABSTRACT

Breast cancer is the most common malignant neoplasm diagnosed during pregnancy. Metaplastic carcinoma is a rare type of breast cancer, representing 1.5% out of all kinds. This is a case report of metaplastic carcinoma in a pregnant woman aged 39 years.

**KEYWORDS:** Breast cancer; pregnancy; mastectomy, modified radical.

### RESUMO

O câncer de mama é a neoplasia maligna mais comumente diagnosticado durante a gestação. O carcinoma metaplásico é um tipo raro de câncer mamário que representa 1,5% de todos os tipos. A seguir, é relatado um caso de carcinoma metaplásico em gestante de 39 anos.

**PALAVRAS-CHAVE:** Câncer de mama; gestação; mastectomia radical modificada.

<sup>1</sup>Hospital do Açúcar – Maceió (AL), Brazil.

<sup>2</sup>MedRadius – Maceió (AL), Brazil.

<sup>3</sup>Hospital Universitário Professor Alberto Antunes – Maceió (AL), Brazil.

<sup>4</sup>Universidade Federal de Alagoas – Maceió (AL), Brazil.

\*Corresponding author: linsraiana@gmail.com

Conflict of interests: nothing to declare.

Received on: 05/30/2018. Accepted on: 07/14/2018

## INTRODUCTION

Breast cancer is the most common malignant neoplasm diagnosed during pregnancy<sup>1</sup>. Its incidence is approximately 1 in every 3 thousand pregnancies<sup>2,3</sup>. Metaplastic breast carcinoma is a rare type of tumor that represents 0.25 to 1.5% out of all kinds of breast cancer<sup>4,5</sup>. The 5-year survival rate is around 49 to 68%<sup>5</sup>. Usually, this neoplasm is a palpable breast mass in women older than 50 years<sup>4</sup>. The present work is a case report of metaplastic breast carcinoma in a pregnant woman aged 39 years.

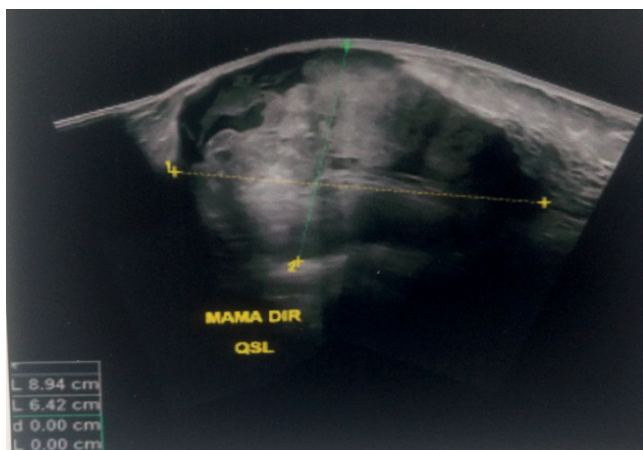
## CASE REPORT

E.L.S., 39 years old, G2P1A0, 23 weeks of gestational age. She visits the oncology surgery unit complaining of hyperemia in the right breast, as well as itching and a fast-growing nodule in the prior month. The patient reported a history of fibroadenoma in the right breast in the past year, followed by the mastology department. She had a positive family history of breast cancer (mother with the first tumor at 39 years old and second at 68 years old). She denies smoking and other comorbidities. The examination revealed a tumor in the right breast of approximately 10 × 8 cm and palpable lymph nodes in the right axilla. Breast ultrasonography showed a heterogeneous nodular image, with anechoic and solid echogenic areas, vascularization on Doppler, measuring approximately 10.3 × 7.1 × 8.8 cm, located at the upper outer quadrant of the right breast, with close contact with the skin and deep muscle planes, classified as BI-RADS US 4C (Figure 1). The axillary investigation identified lymph nodes of normal aspect, with the largest measuring 1.1 × 0.6 cm. The core biopsy of the lesion detected a poorly differentiated invasive breast carcinoma (variant of squamous cells – grade III). Other requested laboratory tests were within normal limits. The treatment chosen was modified radical mastectomy with lymph node dissection, adjuvant chemotherapy, and, after delivery, radiotherapy. Histopathological examination of

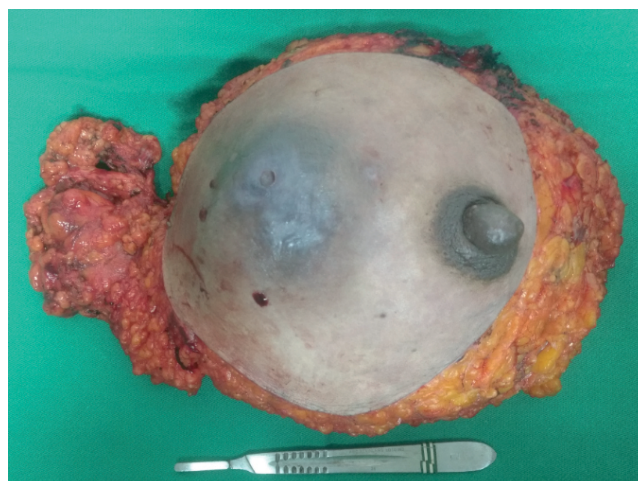the surgical specimen (16 × 11.5 × 6 cm) (Figure 2) revealed metaplastic carcinoma with a predominance of squamous cell carcinoma, moderately differentiated, without vascular invasion, free margins, and lack of lymph node metastasis in the 37 lymph nodes resected. The chemotherapy regimen chosen was anthracycline, cyclophosphamide, and taxane.

## DISCUSSION

Pregnancy-related breast cancer includes those diagnosed during pregnancy or up to one year after delivery. Breast cancer detected during the first trimester of pregnancy limits the treatment options, delaying chemotherapy until the second trimester, as the fetus is at lower risk in this stage<sup>1</sup>. Breast cancer during pregnancy is associated with a worse prognosis, both for the diagnosis in more advanced stages and the limitation on chemotherapy and radiotherapy treatment due to the risk of fetal malformation<sup>1</sup>. Surgery is the treatment of choice and can be conducted in all trimesters of pregnancy. Modified radical mastectomy is the preferred approach since radiotherapy for breast conservation cannot be administered<sup>3</sup>. Metaplastic breast carcinoma (MBC) is defined as a mixture of epithelial and sarcomatoid components, can be histologically classified as purely epithelial or mixed epithelial and mesenchymal<sup>4,6</sup>, and is the most common squamous cell carcinoma<sup>6</sup>. Imaging tests presented characteristics similar to invasive ductal carcinoma and benign lesions, with mammography showing irregular or circumscribed masses with spiculated area and ultrasonography indicating a heterogeneous cystic mass<sup>4,6</sup>. MBC is characterized by a large fast-growing mass, often triple-negative for estrogen, progesterone, and HER2 receptors<sup>1,4</sup>. Less than 20% of cases are hormone receptor positive<sup>7,8</sup>. It has a greater chance of hematogenous than lymphatic metastasis, with axillary lymph node involvement ranging from 8 to 40% of cases, and presents a high rate of systemic metastasis<sup>4,7,9</sup>, being more common in the



**Figure 1.** Right breast ultrasonography showing heterogeneous nodular image.



**Figure 2.** Surgical specimen (right breast).

lungs, brain, thyroid, chest wall, and abdominal cavity. Local recurrence occurs in approximately 8 months to 5 years after lesion excision<sup>7</sup>. Onset before 40 years of age, skin invasion, and lymph node involvement are predictors of poor prognosis<sup>4,6</sup>. In the case reported, the patient presented predictors of poor prognosis, such as being 39 years old and skin involvement; however, she did not have lymph node metastasis. A study by Rakha et al. showed that the squamous, fusiform, and mixed fusiform subtypes have a worse prognosis. In the present work, the histopathological diagnosis revealed a predominance of the squamous cell subtype<sup>5</sup>. A study conducted in Saudi Arabia by Altaf et al. identified MBC in two pregnant women — one of them with a recent history of abortion — out of seven patients. Their immunohistochemistry presented cells morphologically similar to syncytiotrophoblasts, indicating choriocarcinomatous differentiation, with more aggressive behavior<sup>10</sup>. There is no consensus on the ideal treatment for MBC; however, surgery with axillary staging and chemotherapy has been currently adopted. Radiotherapy is also indicated when the tumor is larger than 5 cm or has more than four lymph node metastases<sup>1,4</sup>. Rakha et al. found that chemotherapy is associated with better outcomes, despite having effect limited to cases in initial stages<sup>5</sup>. The literature has extremely limited data on neoadjuvant chemotherapy, making it impossible to establish what their results would be<sup>8</sup>. Taxane-based chemotherapy has shown good results<sup>6</sup>. In a study conducted in 2015, Aydiner et al. verified that adjuvant radiotherapy improved patient survival<sup>9,11</sup>. In the case reported, the treatment chosen was modified radical mastectomy with lymph node dissection, as the patient could not undergo

radiotherapy for breast preservation due to her pregnancy, even with a tumor larger than 5 cm. In addition, the tumor extension did not leave margins to perform conservative surgery and presented palpable axillary lymph nodes. Besides the surgery, the patient underwent adjuvant chemotherapy, since she was already in the second trimester of pregnancy, and radiotherapy after delivery due to the large tumor size.

## CONCLUSION

Breast cancer during pregnancy has shown worse prognosis due to limitations on the use of radiotherapy and chemotherapy because of the risk of fetal malformation. Thus, the treatment of choice is surgery and chemotherapy after the second trimester, with the preferred approach being modified radical mastectomy. In this population group, metaplastic breast carcinoma has a high incidence, particularly the squamous cell subtype. The image shows a fast-growing heterogeneous cystic mass, with a higher chance of hematogenous metastases, particularly to the lungs, brain, thyroid, chest wall, and abdominal cavity. It is important to promptly diagnose and treat MBC due to its aggressive nature, capable of rapid growth and systemic metastasis. We should try to preserve the integrity of the fetus by adopting less aggressive treatments and waiting for a lower risk period to start more effective therapies. However, the ultimate goal is the maternal treatment.

The authors declare that the patient allowed publication of the case after signing the Informed Consent Form (ICF).

## REFERENCES

1. Framarino-Dei-Malatesta M, Piccioni MG, Brunelli R, Iannini I, Casciagli G, Sammartino P. Breast cancer during pregnancy: A retrospective study on obstetrical problems and survival. *Eur J Obstet Gynecol Reprod Biol.* 2014;173(1):48-52. <https://doi.org/10.1016/j.ejogrb.2013.11.017>
2. Gropper AB, Calvillo KZ, Dominici L, Troyan S, Rhei E, Economy KE, et al. Sentinel lymph node biopsy in pregnant women with breast cancer. *Ann Surg Oncol.* 2014;21(8):2506-11. <https://doi.org/10.1245/s10434-014-3718-2>
3. McMaster J, Dua A, Desai SS, Kuy SR, Kuy SR. Short term outcomes following breast cancer surgery in pregnant women. *Gynecol Oncol.* 2014;135(3):539-41. <https://doi.org/10.1016/j.ygyno.2013.09.006>
4. McKinnon E, Xiao P. Metaplastic carcinoma of the breast. *Arch Pathol Lab Med.* 2015;139(6):819-22. <https://doi.org/10.5858/arpa.2013-0358-RS>
5. Rakha EA, Tan PH, Varga Z, Tse GM, Shaaban AM, Climent F, et al. Prognostic factors in metaplastic carcinoma of the breast: A multi-institutional study. *Br J Cancer.* 2015;112(2):283-9. <https://doi.org/10.1038/bjc.2014.592>
6. Surenkok S, Tahberer E, Cinkaya A, Kodaz H, Deger A. Metaplastic breast cancer: A case report. *J Pak Med Assoc.* 2018;68(3):466-8.
7. Zhu J, Li K, Dong X, Zhou P, Li P, Bi J. Metaplastic breast carcinoma composed of epithelial – myoepithelial carcinoma and squamous cell carcinoma. *Medicine (Baltimore).* 2018;97(15):e0364. <https://doi.org/10.1097/MD.0000000000010364>
8. Sanguinetti A, Lucchini R, Santoprete S, Farabi R, Fioriti L, Bistoni G, et al. Metaplastic carcinoma of the breast: treatment, results and prognostic factors based on international literature. *Ann Ital Chir.* 2014;85(2):109-13.
9. Aydiner A, Sen F, Tambas M, Ciftci R, Eralp Y, Saip P, et al. Metaplastic breast carcinoma versus triple-negative breast cancer: Survival and response to treatment. *Medicine (Baltimore).* 2015;94(52):e2341. <https://dx.doi.org/10.1097%2FMD.0000000000002341>
10. Altaf FJ, Mokhtar GA, Emam E, Bokhary RY, Mahfouz NB, Al Amoudi S, et al. Metaplastic carcinoma of the breast: An immunohistochemical study. *Diagn Pathol.* 2014;9(1):139. <https://doi.org/10.1186/1746-1596-9-139>
11. Gultekin M, Eren G, Babacan T, Yildiz F, Altundag K, Guler N, et al. Metaplastic breast carcinoma: A heterogeneous disease. *Asian Pacific J Cancer Prev.* 2014;15(6):2851-6.