

TREATMENT OF GIANT JUVENILE FIBROADENOMA: RESULT AFTER MINIMALLY INVASIVE APPROACH WITHOUT RECONSTRUCTIVE SURGERY

Tratamento do fibroadenoma gigante juvenil:
abordagem minimamente invasiva sem cirurgia reconstrutora

Cátia Cilene Aires Lima^{1*}, Renilton Aires Lima¹

ABSTRACT

Fibroadenomas are common benign tumors of the female breast. Those that present as rapidly growing breast tumors exceeding 5 cm in diameter or 500 g in weight in young female patients are commonly classified as giant juvenile fibroadenomas. These tumors are rare, and due to their excessive growth, they are usually enucleated to clarify a malignant origin, to differentiate from phyllodes tumor and to prevent persisting deformities of the breast. This report details the surgical approach to this clinical problem in a 14-year-old female with functional preservation of the breast and a good esthetic result.

KEYWORDS: Fibroadenoma; breast; fibrocystic breast disease.

RESUMO

Fibroadenomas são tumores benignos comuns da mama feminina. Aqueles que apresentam rápido crescimento excedendo a 5 centímetros de diâmetro ou que pesam mais que 500 gramas em mulheres jovens são classificados como fibroadenomas gigantes juvenis. Estes tumores são raros e, devido seu excessivo crescimento, são comumente enucleados para descartar uma origem maligna, diferenciar de tumores filóides e para evitar deformidades da mama. Este relato de caso detalha uma abordagem cirúrgica em uma adolescente de 14 anos com preservação da mama e bom resultado estético.

PALAVRAS-CHAVE: Fibroadenoma; mama; doença da mama fibrocística.

¹Mastology Service, Hospital Márcio Cunha – Ipatinga (MG), Brazil.

*Corresponding author: catia12aires@hotmail.com

Conflict of interests: nothing to declare.

Received on: 02/12/2018. **Accepted on:** 07/14/2018

INTRODUCTION

Fibroadenomas are common estrogen-sensitive benign tumors that can develop from breast lobules and stroma¹. The term “giant juvenile fibroadenoma” is used to describe a fibroadenoma in young female patients if it is greater than 5 cm, 500 grams, or replaces at least four fifths of the breast². These lesions can become very large and cause prominent asymmetry of the breasts by stretching the areola complex and distorting the dermal tissue³.

Giant fibroadenomas are usually enucleated to clarify a malignant origin, to differentiate from phyllodes tumor and to prevent persisting deformities of the breast⁴.

Many techniques in surgical extirpation have been described to optimize esthetics and minimize distortion. We describe an excision of a 12-centimeter giant juvenile fibroadenoma using a strategically incision without subsequent reconstruction, which resulted in good esthetics and contour of the breast.

CASE REPORT

A 14-year old female patient was referred, by her pediatrician, to our breast surgery clinic with large mass of the breast, causing significant breast asymmetry and being a source of severe psychosocial stress. According to the patient's information, an asymptomatic enlargement of the left breast was first noticed about 2 months ago.

Physical examination revealed a markedly enlarged left breast containing a 12 cm palpable mobile mass, ptosis and important nipple-areola stretching (Figure 1). The mass was movable, soft, well defined and painful on palpation. No suspect lymph nodes were detected. The skin of the breast was stretched, with dilated veins. The breast wasn't tender and had no erythema or evidence of infection. The right breast was normal in size, shape

and contour, but a 2 cm nodule was detected in the upper outer quadrant, well circumscribed and mobile.

The patient did not report any other symptoms and had no personal history of breast pathology or family history of breast cancer, with no previous operations, medical conditions or allergies, and had never undergone hormonal treatment.

Breast ultrasound demonstrated a well-circumscribed, heterogeneous mass of 11.6 × 9.2 cm almost occupying the entire left breast, as well as a homogenous isoechoic mass of 2 × 1.1 cm in the right breast.

Core biopsy of the left breast mass was performed to rule out phyllodes tumor or underlying malignancy.

Based on the clinical and histological findings, a preliminary diagnosis of a giant juvenile fibroadenoma was made.

An excisional biopsy of the lesion was performed using a 4 cm circum-areolar incision under general anesthesia. The malleable and pliable nature of these tumors makes it possible to remove them intact, without the need to extend the incision or morcellation measuring 12 × 12 × 7 cm (Figure 2). The wound was irrigated and hemostasis obtained. The skin was closed primarily without any approximation or reconstruction of breast tissue and the wound was covered using pressure dressing for 24 hours. The patient was discharged from hospital on the second postoperative day (Figure 3).

The specimen was submitted to pathology. A juvenile giant fibroadenoma was confirmed with no atypical features and no evidence of phyllodes tumor.

The patient was observed at the clinic 1 month after the excision without any postoperative complications.

Twenty-four months after surgery, she did not show any recurrence. The little nodule in the right breast remained stable and mild breast asymmetry is present, but the patient is satisfied with the result.

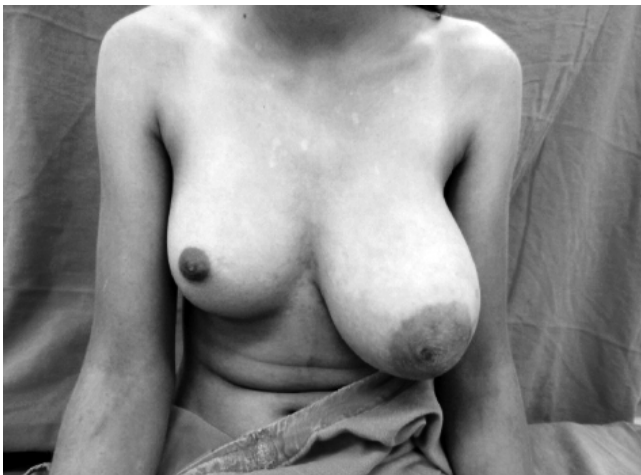


Figure 1. Preoperative photograph of a patient with a large right breast mass causing significant asymmetry to the breasts.

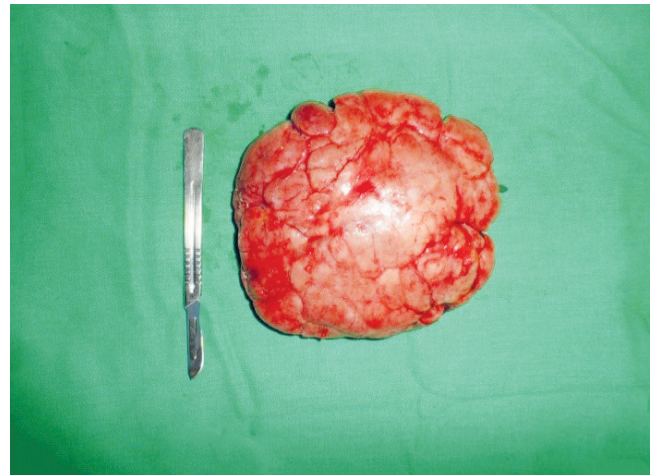


Figure 2. Gross pathology specimen of a large juvenile fibroadenomas removed.

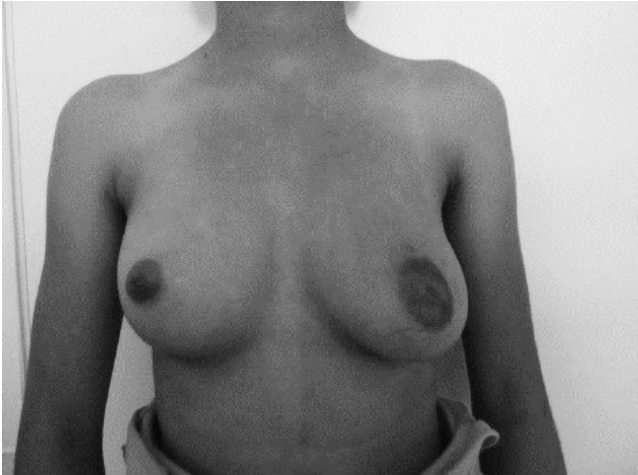

Figure 3. Postoperative photograph of the patient, showing breast preservation with a good cosmetic outcome.

DISCUSSION

Breast masses in young patients are usually benign in nature but may cause considerable concern due to pain and breast's cosmesis³. Fibroadenoma is the most common breast tumor in adolescent girls, as noted in 70 to 95% of breast biopsies in this age group¹. Giant juvenile fibroadenomas are rare, accounting for only 0.5 to 2% of the total diagnosed fibroadenomas and are differentiated from the simple ones based on their large sizes, occasional rapid growth, and the young patient's age⁵.

Currently, there is a lack of clear guidelines regarding diagnostic and treatment modalities, and management varies among breast surgeons, obstetricians/gynecologists, pediatricians, and pediatric surgeons, all of whom may encounter a patient with a giant juvenile fibroadenoma⁶.

Breast ultrasound is the usual modality of choice to image breast masses in adolescents³. Ultrasound is a non-invasive diagnostic method that can determine whether a mass is solid or cystic². Magnetic resonance imaging (MRI) and mammography have not been recommended for use in adolescents due to the density of breast tissue in this population⁷. The use of fine needle aspiration and core needle biopsy may be used in the rapidly enlarging lesion to rule out a frank malignancy^{2,5}.

Phyllodes tumor, as the main differential diagnosis to a giant fibroadenoma, is rare in adolescence, but diagnosis should be considered in all fast-developing breast masses due to the fact that there are rare malignant types which may metastasize⁴. Neither ultrasound nor mammography or MRI, as well as fine needle aspiration, is shown to be helpful to differentiate fibroadenoma from phyllodes tumor⁸.

Juvenile fibroadenomas may present a challenge for physicians, as treatment guidelines are lacking among this population, there is limited data on long-term outcomes after fibroadenoma excision and no recommendations have been made regarding the optimal timing of reconstructive surgery if needed⁷.

Surgical management of these lesions reported in medical literature ranges from simple excision, to breast conservation, to mastectomy with different types of breast reconstruction⁵. A breast incision with enucleation should be considered the standard for giant juvenile fibroadenoma with preservation of maximal breast tissue². Surgical technique emphasizing minimal dissection through ducts and lobules and thermal injury to the breast also help prevent injury to the developing breast tissue⁵.

Because cosmesis is an important factor when removing a benign lesion, a small surgical incision will enhance cosmetic outcomes^{8,9}. However, the size and location of the mass may ultimately guide the incision location and length^{7,10}.

Patients may experience postoperative esthetic deformity or secondary asymmetry, especially after the removal of a giant fibroadenoma, but reconstructive surgery is usually not considered until at least one year after the procedure⁷.

Additionally, once these lesions are removed, normal breast tissue will re-expand, and to some degree, remodel⁵. These two factors can allow a very large juvenile fibroadenoma to be removed with little or no esthetic deformity to the adolescent breast⁵.

In conclusion, when confronted with large breast masses in adolescence, the surgeon attempting to remove them should be aware that the breast can be preserved with excellent cosmesis and retention of function. Using a circum-areolar incision we were able to dissect the mass away from the developing breast parenchyma with minimal parenchymal damage. Total enucleation of the mass should be performed and does not require supplemental procedures.

REFERENCES

1. Greydanus DE, Matytsina L, Gains M. Breast disorders in children and adolescents. *Prim Care*. 2006;33(2):455-502. <https://doi.org/10.1016/j.pop.2006.02.002>
2. Sosin M, Feldman E. Giant juvenile fibroadenoma: a case and review of novel modalities in treatment. *Breast Dis*. 2012;34(1):35-8. <https://doi.org/10.3233/BD-130342>
3. Matz D, Kerivan L, Reintgen M, Akman K, Lozicki A, Causey T, et al. Breast preservation in women with giant juvenile fibroadenoma. *Clin Breast Cancer*. 2013;13(3):219-22. <https://doi.org/10.1016/j.clbc.2012.10.003>
4. Heilmann T, Leuschner I, Hilpert F, Kümper C, Strauss A, Mundhenke C, et al. Diagnosis and management of an unilateral giant fibroadenoma of the breast in pregnancy. *Arch Gynecol Obstet*. 2012;285(1):235-7. <https://doi.org/10.1007/s00404-011-1923-9>

5. Biggers BD, Lamont JP, Etufugh CN, Knox SK. Inframammary approach for removal of giant juvenile fibroadenomas. *J Am Coll Surg.* 2009;208(6):e1-4. <https://doi.org/10.1016/j.jamcollsurg.2009.02.064>
6. Sosin M, Pulcrano M, Feldman ED, Patel KM, Nahabedian MY, Weissler JM, et al. Giant juvenile fibroadenoma: a systematic review with diagnostic and treatment recommendations. *Gland Surg.* 2015;4(4):312-21. <https://doi.org/10.3978/j.issn.2227-684X.2015.06.04>
7. Cerrato F, Labow BI. Diagnosis and management of fibroadenomas in the adolescent breast. *Semin Plast Surg.* 2013;27(1):23-5. <https://dx.doi.org/10.1055%2Fs-0033-1343992>
8. Fallat ME, Ignacio RC, Jr. Breast disorders in children and adolescents. *J Pediatr Adolesc Gynecol.* 2008;21(6):311-6. <https://doi.org/10.1016/j.jpag.2007.10.007>
9. Cheng PJ, Vu LT, Cass DL, Hicks MJ, Brandt ML, Kim ES. Endoscopic specimen pouch technique for removal of giant fibroadenomas of the breast. *J Pediatr Surg.* 2012;47(4):803-7. <https://doi.org/10.1016/j.jpedsurg.2012.01.064>
10. Hille-Betz U, Klapdor R, Henseler H, Soergel P, Länger F. Treatment of Giant Fibroadenoma in Young Women: Results after Tumor Excision without Reconstructive Surgery. *Geburtshilfe Frauenheilkunde.* 2015;75(9):929-34. <https://dx.doi.org/10.1055%2Fs-0035-1546108>