CASE REPORT
DOI: 10.29289/2594539420180000204

PAGET'S DISEASE IN A MALE PATIENT: CASE REPORT

Doença de paget do mamilo em paciente masculino: relato de caso

Francine Hickmann Nyland[1]*, Patrícia Moreira Rebello da Silva[1], Mário Casales Schorr[1], José Luiz Pedrini[1]

ABSTRACT

Paget's disease is a rare entity that accounts for 1 to 3% of breast tumors. Occurrence in male patients is even less common. Literature has reported only 24 cases in the last 20 years. We described the case of a 62-year-old male patient that sought medical care due to erosion and eczema on left nipple. After skin biopsy, the clinical suspicion of Paget's disease was confirmed by histological and immunohistochemical studies, which enabled the proper surgical and oncological treatment.

KEYWORDS: Paget's disease, mammary; breast; breast neoplasms

RESUMO

A Doença de Paget do mamilo é uma entidade rara, representando 1 a 3% dos carcinomas de mama. Sua presença em pacientes masculinos é ainda menos comum, com apenas 24 casos na literatura nos últimos 20 anos. Em nosso relato de caso, descrevemos um paciente masculino de 62 anos que procurou atendimento por erosão e eczema no mamilo esquerdo. Após biópsia de pele, a histologia e o estudo imuno-histoquímico confirmaram a suspeita clínica de Doença de Paget do mamilo, possibilitando o tratamento cirúrgico-oncológico adequado.

PALAVRAS-CHAVE: Doença de paget mamária; mama; neoplasias da mama.

Study carried out at Hospital Nossa Senhora da Conceição – Porto Alegre (RS), Brazil.
[1]Hospital Nossa Senhora da Conceição – Porto Alegre (RS), Brazil.
***Corresponding author:** fhnyland@gmail.com
Conflict of interests: none.
Received on: 03/01/2017. **Accepted on:** 05/29/2017

INTRODUCTION

Sir James Paget coined the name Paget's Disease following the report of several cases, including 15 patients, in 1874. He firstly believed the disease would be a benign condition, although it was associated with a malignant disorder. In most cases, the lesion manifests as an ulceration or erythema on the nipple with skin scaling, which also evolves with exudate or papillary cluster. Differential diagnosis should include areolar eczema, contact dermatitis, and actinic dermatitis[1]. Diagnosis still poses challenge when it comes to the male population, as men usually seek health services late and incorrect treatments are established due to differential diagnoses and occurrence rarity.

CASE REPORT

A 62-year-old male patient without comorbidities and non-smoker sought medical care in the Mastology Clinics due to one-year evolution erosive lesion on left breast. He had family history of a twin sister who died due to breast neoplasm at age 48 and a brother with skin melanoma. Physical examination showed erosion of the left nipple-areolar complex with hyperemia and skin scaling associated with retroareolar densification, without no other finding (Figure 1). Mammogram showed focal distortion on the left breast's upper side and microcalcifications (Figures 2 and 3). Ultrasound imaging showed hypoechogenic area (not nodule-shaped), with thin formation of posterior acoustic shadowing, hyperechogenic focuses on its inner side, and presence of dermis and hypodermis thickening in areolar region. The patient underwent nipple (skin) biopsy that presented "atypical cells of Paget standard." The results of immunohistochemical study were compatible with Paget's Disease (Figure 4). After diagnosis, the patient received treatment and then mastectomy and sentinel lymph node investigation were conducted. The definite anatomopathological examination also showed a 2.2-cm ductal carcinoma in situ on retro-areolar region, which was associated with invasive breast carcinoma. The sentinel lymph node tested negative for metastases. After surgical recovery, the patient received chemotherapy with cyclophosphamide and docetaxel, and then adjuvant tamoxifen. He has been on medical follow-up for a year without evidence of recurrence.

Figure 2. Mammography with evidence of architectural distortion and microcalcifications (left craniocaudal view).

Figure 1. Lesion with erosion in left nipple-areolar complex.

Figure 3. Mammography with evidence of architectural distortion and microcalcifications (left medial and lateral oblique views).

DISCUSSION

Paget's Disease is a rare presentation of breast cancer that accounts for 1 to 3% of all cases. Occurrence in men is even rarer (24 cases have been reported in literature since 1997)[2]. Most lesions are associated with adjacent breast malignant disease; however, it can also coexist with carcinoma in situ or in its pure form[3]. The classical risk factors for male breast neoplasm are described in patients with Paget's Disease—mutations in BRCA 1 and 2 genes (Breast Cancer 1 and 2), Klinefelter syndrome, previous exposure to radiation, endocrine alterations with tendency to hyperstrogenism, among others. Nevertheless, there is not enough evidence of their association with this specific pathology.

Clinically, most patients present with eczema or nipple ulceration which have been present for several months. Pruritus, serous exudate, crusts, and papillary cluster may also be present[1]. Differential diagnosis must be performed with conditions such as nipple eczema, psoriasis, nipple adenomatosis, melanoma, contact dermatitis, and actinic dermatitis[2].

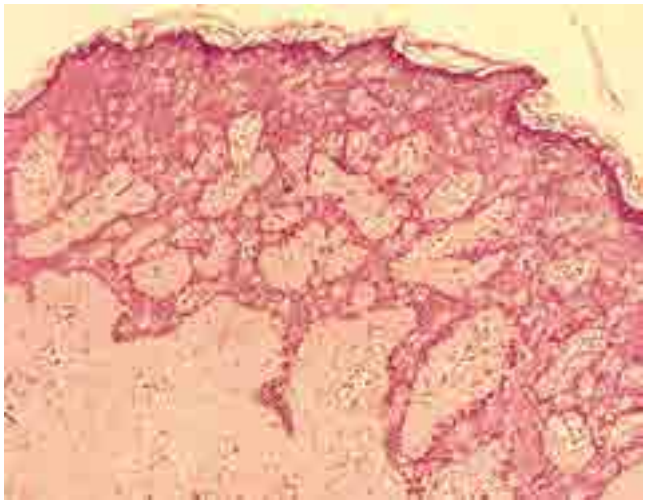

Figure 4. Histological cut of areolar tissue showing epidermis invasion by Paget's cells with abundant cytoplasm, vesicular nucleus, and prominent nucleoli.

This type of neoplasm is histologically characterized by nipple epidermis infiltration with aggregates of large and ovoid tumoral cells, with abundant cytoplasm, vesicular nucleus, and prominent nucleoli (Figure 4)[4].

Imaging findings are not specific. The mammographic examination has only 34% sensitivity, but it is useful to evaluate disease extension in the event of findings[5]. Ultrasound imaging is also used, especially when the mammography is negative for tumors.

Kim et al. (2010) found that magnetic resonance imaging (MRI) with contrast revealed morphological alterations in 87.5% of the lesions diagnosed as Paget's disease compared to 20.0% by mammogram and 60.0% by ultrasound. In addition, MRI shows the lesion in mammary parenchyma in 100% of cases[6]. Thus, breast MRI has been more used, with studies of small series that demonstrate advantages, especially when it comes to spotting an occult disease[1].

Paget's disease prognosis in men is quite worse compared to the female population and depends mainly on the adjacent malignant disease. Mastectomy is the most used treatment for men—with axillary emptiness or sentinel lymph node investigation—, with adjuvants according to the general principles of breast neoplasm treatment.

CONCLUSION

Reports related to Paget's Disease of the breast in males are rare in the literature. Many considerations and recommendations for the diagnosis and treatment of this pathology are obtained from studies conducted with females. Therefore, the difference of prognosis for women and men is still the target of questioning. Hence, it is greatly important to suspect and recommend biopsy in alterations of men's nipple aiming at providing patients with an early treatment.

REFERENCES

1. Harris JR, Lipmann ME, Morrow M, Osborne CK. Diseases of The Breast. 5th ed. Philadelphia: Wolters Kluwer Health. 2014;838-46.
2. Adams SJ, Kanthan R. Paget's disease of the male breast in the 21st century: A systematic review. The Breast. 2016;29:14-23.
3. Mujgan C, Gatti G, Sosnovskikh I, Rotmensz N, Botteri E, Musmeci S, et al. Paget's disease of the breast: the experience of the European Institute of Oncology and review of the literature. Breast Cancer Res Treat. 2008;112:513-21.
4. Lloyd J, Flanagan AM. Mammary and extramammary Paget's disease. J Clin Pathol. 2000;53:742-9.
5 Günhan-Bilgen I, Oktay A. Paget's disease of the breast: clinical, mammographic, sonographic and pathologic findings in 52 cases. Eur J Radiol. 2006;60(2):256-63.
6. Kim HS, Seok JH, Cha ES, Kang BJ, Kim HH, Seo YJ. Significance of nipple enhancement of Paget's disease in contrast enhanced breast MRI. Arch Gynecol Obstet. 2010;282:157-62.