

# CLINICAL, MAMMOGRAPHIC AND HISTOPATHOLOGICAL CORRELATION OF BREAST CANCER IN WOMEN AGED BETWEEN 50 AND 70 YEARS

## Correlação clínica, mamográfica e histopatológica do câncer mamário em mulheres com idade entre 50 e 70 anos

Mariana Meira Vieira<sup>1</sup>, Beatriz Regina Alvares<sup>2\*</sup>, Orlando José de Almeida<sup>3</sup>, Rodrigo Menezes Jales<sup>4</sup>

### ABSTRACT

**Objective:** To correlate the clinical, mammographic and histopathological findings of women aged between 50 and 70 years old who were diagnosed with breast cancer and were assisted between 1998 and 2013 at the Mastology Outpatient Clinic of the Center for Full Attention to Women's Health in Universidade Estadual de Campinas (CAISM-Unicamp). **Methods:** This was a cross-sectional and retrospective study, in which the medical records and mammograms of 160 women were analyzed, a sufficient sample size for the statistical analysis. The variables used for comparison were the clinical, mammographic and histopathological findings, analyzed through descriptive and associative statistics. **Results:** Of the 160 cases analyzed, 76.9% were symptomatic, and the main clinical findings included palpable nodule (68.1%) and skin alterations (30%). The prevalent mammographic presentations in asymptomatic women were microcalcifications (48.7%), nodules (43.2%) and architectural distortion (8.1%). Regarding the histological type, 81.3% presented invasive ductal carcinoma (IDC) and 10.7%, ductal carcinoma *in situ* (DCIS). **Conclusion:** The present study showed that there was a predominance of symptomatic women with mammographic presentation of spiculated nodules and histological type of IDC. In the other patients with lesions detected in the screening test, pleomorphic microcalcifications were prevalent as the main finding of DCIS. Diagnostic mammography was the main form of detection of breast cancer, which may represent the lack of access of these women to screening or early detection of malignant lesions. This reveals the need to improve control actions and care protocols of these patients.

**KEYWORDS:** Breast cancer; women; mammography; histology; diagnosis.

### RESUMO

**Objetivo:** Correlacionar os achados clínicos, mamográficos e histopatológicos de mulheres na faixa etária entre 50 e 70 anos que tiveram diagnóstico de câncer mamário e foram atendidas, entre 1998 e 2013, no Ambulatório de Mastologia do Centro de Atenção Integral à Saúde da Mulher da Universidade Estadual de Campinas (CAISM-Unicamp). **Métodos:** Trata-se de um estudo de corte transversal e retrospectivo, no qual foram analisados os prontuários e as mamografias de 160 mulheres, tamanho amostral suficiente para a análise estatística. As variáveis usadas para comparação foram os achados clínicos, mamográficos e histopatológicos, analisados por meio da estatística descritiva e associativa. **Resultados:** Entre os 160 casos analisados, 76,9% eram sintomáticos e os principais achados clínicos incluíram nódulo palpável (68,1%) e alterações de pele (30%). As apresentações mamográficas prevalentes nas mulheres assintomáticas foram microcalcificações (48,7%), nódulos (43,2%) e distorção arquitetural (8,1%). Com relação ao tipo histológico, 81,3% apresentaram carcinoma ductal invasivo (CDI) e 10,7%, carcinoma ductal *in situ* (CDIS). **Conclusão:** O presente trabalho evidenciou que houve uma predominância de mulheres sintomáticas, com apresentação mamográfica de nódulos espiculados e tipo histológico de CDI. Já nas demais pacientes com lesões detectadas no exame de rastreamento predominaram as microcalcificações pleomórficas como o principal achado do CDIS. A mamografia diagnóstica foi a principal forma de detecção do câncer mamário, podendo representar a falta de acesso dessas mulheres aos exames de rastreamento ou à não detecção precoce das lesões malignas, o que revela a necessidade de melhorar as ações de controle e os protocolos de atendimento dessas pacientes.

**PALAVRAS-CHAVE:** Câncer mamário; mulheres; mamografia; histologia; diagnóstico.

Study carried out at the Center for Full Attention to Women's Health in Universidade Estadual de Campinas – Campinas (SP), Brazil.

<sup>1</sup>School of Medical Sciences, Universidade Estadual de Campinas (Unicamp) – Campinas (SP), Brazil.

<sup>2</sup>Department of Radiology, School of Medical Sciences, Unicamp – Campinas (SP), Brazil.

<sup>3</sup>Radiology Section, Center for Full Attention to Women's Health, Unicamp – Campinas (SP), Brazil.

<sup>4</sup>Department of Tocogynecology, Unicamp – Campinas (SP), Brazil.

\*Corresponding author: alvaresb@terra.com.br

**Conflict of interests:** nothing to declare.

**Received on:** 10/06/2016. **Accepted on:** 06/06/2017

## INTRODUCTION

Worldwide, breast cancer is the leading cause of death among women<sup>1</sup>. Studies indicate that women aged more than 50 years are the ones most frequently affected by breast cancer, representing the highest mortality rate due to this disease<sup>2</sup>. In Brazil, in 2016, 57,960 new cases of breast cancer were estimated, with an estimated risk of 56.2 cases per 100,000 women<sup>3</sup>.

Clinical signs of breast cancer are the bulging or retraction of the skin, including the nipple area, the thickening of the skin, abnormal secretion at the nipple, and palpable breast and/or axillary nodules. In cases in which breast cancer is not detected early, these clinical signs may represent the first perception of an abnormality already at an advanced stage<sup>4</sup>.

For the early detection of breast cancer, mammography is considered a highly effective exam, since it allows the identification of subclinical changes such as microcalcifications (MCs), which may represent the first signs of malignancy<sup>5</sup>. This test should be performed on asymptomatic women at regular intervals<sup>5</sup>. According to recent systematic reviews, the impact of mammographic screening on reducing breast cancer mortality may reach 35%<sup>6,7</sup>.

The Ministry of Health recommends the annual clinical examination of the breasts, starting at the age of 40, for the early detection of female breast cancer. Mammographic screening should be performed in women aged between 50 and 69 years, with a maximum interval of two years in between the examinations. Finally, the practice of clinical examination of the breasts and annual mammography is recommended starting at the age of 35, for women belonging to population groups at high risk of developing breast cancer<sup>4</sup>.

In recent years, Brazil has been presenting a new demographic pattern generated by the reduction of the population growth rate and the increasing life expectancy, resulting in a significant increase in the number of elderly people<sup>8</sup>. In this context, it is relevant to recognize the specificities of breast neoplasms, as well as in which stage these cancers are being diagnosed in women in the age group between 50 and 70 years. These data, associated with the age group, should be considered as important factors in the choice of the most appropriate treatment and in the health policies for the patients.

Although mammography is the basis of screening, therapeutic decisions and prognostic estimates depend on the histopathological diagnosis, classification and extent of lesions<sup>9</sup>. The most common histological type is invasive ductal carcinoma (IDC), which accounts for 80 to 90% of breast carcinomas<sup>10</sup>.

Data from the literature describe higher incidence of ductal carcinoma *in situ* (DCIS) in the mammographic presentations of a cluster of pleomorphic microcalcifications, and higher incidence of IDC in mammographic presentations of irregularly shaped nodules and spiculated margins<sup>11</sup>.

Although there are several studies that associate the mammographic presentation with the histopathological presentation of breast cancer, there are still few and controversial analyses that relate the clinical, mammographic and histopathological presentation of breast cancer in women in this age group. Authors have already demonstrated that MCs may be present in 90% of DCIS cases and in 40% of IDC cases<sup>12</sup>. Therefore, it is important to be fully aware of the characteristics of MCs and their association with the histological type of breast cancer.

In view of this information, the present study correlated clinical, mammographic and histopathological data in women aged between 50 and 70 years who had been diagnosed with breast cancer, and evaluated the most relevant factors in these associations.

## METHODS

A cross-sectional and retrospective study was carried out. The medical records and mammograms of 160 women with breast cancer diagnosed in the age group between 50 and 70 years old were studied at the Mastology Outpatient Clinic of CAISM-Unicamp, from 1998 to 2013.

The researchers met the requirements of Resolution 196/1996 regarding the ethical aspects and this research was approved by the Research Commission of CAISM, protocol number 008/2014. No direct procedures were performed with patients, which justifies the request for waiver of the Informed Consent Form.

The variables included in the study were clinical, mammographic and histopathological findings. These data were collected by one of the researchers by the review of medical records. Mammographic exams were analyzed by the physicians at the Image Service of CAISM-Unicamp, all experienced in mammography.

Clinical variables included age (established in full years), presence of palpable nodule, skin changes (including retraction or thickening of the skin), and papillary discharge.

Mammographic variables included the breast density pattern, defined according to the level of replacement of the fibroglandular parenchyma with adipose tissue, being classified into four patterns according to the Breast Imaging Reporting and Data System (BIRADS):

- fat deposition in the breasts (fibroglandular parenchyma almost completely liposubstituted);
- breasts with accentuated liposubstitution (fibroglandular parenchyma dispersed);
- heterogeneously dense breasts (minor replacement with adipose tissue, which may obscure small nodules); and
- extremely dense breasts (extremely dense fibroglandular parenchyma, which reduces the sensitivity of the method)<sup>13</sup>.

The other mammographic variables were the primary and secondary findings<sup>13</sup>. Through the BIRADS system, the former comprise the ones most typically associated with breast cancer. Our study includes as variables the following primary findings:

- nodule;
- microcalcifications; and
- architectural distortion.

Secondary mammographic findings are those that may be associated with the diagnosis of breast cancer, but are considered of importance when identified with primary findings. The most frequent secondary findings that were variables of this study are:

- skin retraction;
- skin thickening; and
- nipple retraction.

Nodules visible on both mammographic incidences were evaluated for shape (round, oval, macrolobulated or irregular), margins (circumscribed, microlobulated, poorly defined or spiculated), size (defined in cm) and association with MCs<sup>13</sup>.

MCs, present in craniocaudal (CC) and mid-lateral oblique (MLO) incidence, were described for morphology (monomorphic, pleomorphic and amorphous) and distribution (grouping, linear, segmental or branched)<sup>13</sup>.

Architectural distortion was present when characterized by fine and radiated spikes converging to a point in both mammographic incidences<sup>14</sup>. Histopathological types were classified as IDC, CDIS and others (covering the other histological types of breast cancer)<sup>14</sup>.

The sample comprised 160 patients, which is sufficient for the statistical analysis of this research using the method by Nisen and Schwertman, requiring 10 subjects per predictive variable<sup>15</sup>. The variables included were:

- age;
- palpable nodule;
- skin changes;
- papillary discharge;
- primary mammographic findings (nodules, microcalcifications and architectural distortion);
- secondary mammographic findings (skin thickening, skin retraction and nipple retraction); and
- histological type (CDIS, IDC and others).

Based on these data, it is estimated that the sample should be composed of at least 130 patients.

The medical records of 160 women assisted consecutively between 1998 and 2013 were selected from a database of the Mastology Section of CAISM. The inclusion criteria were: patients aged between 50 and 70 years, diagnosed with breast cancer and assisted at the Mastology Outpatient Clinic of

CAISM between 1998 and 2013. Cases that did not fit these criteria were excluded.

Data collection sheets especially prepared for this study were used, containing the clinical, mammographic and histopathological information of each patient. The data obtained were typed twice in the Excel software due to quality control, to check for inconsistency in the insertion of information. Later, it was organized and stored in a specific database.

The analysis of the collected data was conducted through descriptive statistics with simple (n) and relative frequencies (%) for the categorical variables, and with the calculations of mean, standard deviation, median and maximum and minimum values for continuous variables. Finally, the association between the categorical variables was verified using the  $\chi^2$  or Fisher's exact tests, and the comparison between groups in relation to numerical variables was performed using the Mann-Whitney or Kruskal-Wallis tests. The level of significance was 5%. Data were analyzed using the SAS software, version 9.4.

## RESULTS

In total, 160 charts and mammograms of women with breast cancer assisted at the Mastology Outpatient Clinic of CAISM-Unicamp were reviewed. The mean age was 61 years; the mean age of asymptomatic women was 60.8 years, and the mean age of symptomatic women was 60.9, with no significant statistically difference.

The most frequent breast pattern among the women in the study was marked by fat deposition, with prevalence of 81 (50.63%) and mean age of 61 years. Whereas the predominance of women with heterogeneously dense breasts was 39 (24.38%) and mean age of 51 years, the number of women with liposubstituted breasts was 33 (20.63%), with mean age of 64 years. The number of women with dense breasts was 7 (4.38%), and mean age of 59 years.

The prevalence of symptomatic women was 123 (76.9%), and 109 (68.1%) had a palpable nodule, 49 (30.6%) presented skin alterations, and 8 (5%), papillary discharge. Asymptomatic women represented 37 (23.1%) of the patients included in the study.

Among the 49 women with skin changes, 45 (91.8%) had a nodule as a primary mammographic finding, with p-value of 0.0173. The presence of papillary discharge was not significantly associated with the mammographic findings (Table 1).

Regarding the primary mammographic findings, 129 (81%) women presented nodule, 24 (15%) had MCs, and 5, (4%) architectural distortion. The presence of secondary mammographic findings was found in 27 (10.1%) cases.

As to the prevalent characteristics of the nodules presented in 129 women, 79 (61.2%) had irregular shape, and 96 (74.4%) had spiculated margins, with mean size of 2.7 cm (Figures 1 and 2).

Regarding the predominant characteristics of MCs present in 24 women, 16 (66.7%) were pleomorphic, and 8 (33.3) were amorphous. Still on MCs, 13 (54.2%) were grouped.

A predominance of 130 (81.3%) IDC, 17 (10.6%) CDIS and 13 (8.1%) other histological types was found in histopathological findings.

Among the 130 women with IDC, 113 (86.9%) showed a nodule as a primary mammographic finding, with  $p < 0.0001$ , 89 (78.8%) had spiculated margins, with  $p$ -value of 0.0029 (Table 2). Among the 17 women with CDIS, 11 (64.7%) had MCs as the primary mammographic finding, with  $p < 0.0001$ , and 4 (36.4%) were grouped, with  $p < 0.0001$  (Table 3).

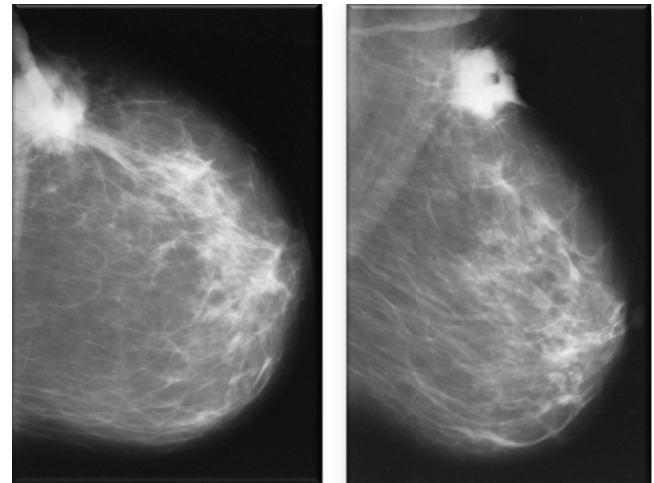
## DISCUSSION

In Brazil, the Ministry of Health recommends mammography screening in women aged between 50 and 69, but the national program is not organized. Therefore, each state and/or city has been carrying out isolated actions aiming at providing access to mammography screening to as many women as possible<sup>7</sup>. So, even if minor, there was an increase in the number of diagnoses of breast cancer in the initial stages in the last 15 years, and the diagnosis of CDIS presented a growth of 0.2 to 6.2%<sup>16</sup>.

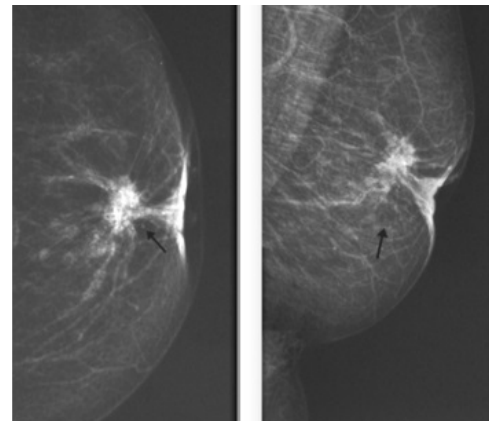
However, studies also show great inequality in these numbers depending on the region of Brazil. A recent analysis demonstrated an increase in breast cancer mortality rates in the North and Northeast States, attributed to the patients' poor access to diagnosis, surgery and chemotherapy<sup>17</sup>.

Although the number of CDIS diagnoses has increased in the last five years, it is still below the rates observed in the countries of Eastern Europe and the United States, ranging from 11 to 25%. Such level was reached due to population screening programs<sup>17</sup>.

Data in the literature also demonstrate great agreement on the efficacy of mammographic screening for early detection and reduction of breast cancer mortality<sup>18</sup>.



**Figure 1.** A 61-year-old patient with a palpable nodule in the left breast. In mammography, the patient presented breasts with accentuated liposubstitution, 3.4 cm irregularly shaped nodule and spiculated margins, in the superolateral quadrant of the left breast, with skin retraction and thickening. The anatomopathological study presented invasive ductal carcinoma.



**Figure 2.** A 62-year-old patient had a palpable nodule in the left breast, skin thickening and nipple retraction. Mammography presents liposubstituted breasts, a 2-cm irregularly shaped nodule, and spiculated margins of retroareolar location in the left breast, associated with microcalcifications. She also presents with nipple retraction, skin retraction and thickening. The anatomopathological study presented invasive ductal carcinoma.

**Table 1.** Association between mammographic presentation and clinical presentation of breast cancer.

Variables	Palpable nodule			Skin changes			Papillary discharge		
	Yes	No	P-Value	Yes	No	P-Value	Yes	No	P-Value
	n (%)	n (%)		n (%)	n (%)		n (%)	n (%)	
Nodule in mammography									
Yes	107 (98.2)	22 (43.1)	<0.0001	45 (91.8)	84 (75.7)	0.0173	8 (100)	121 (79.6)	0.3559
No	2 (1.8)	29 (56.9)		4 (8.2)	27 (24.3)		0 (0)	31 (20.4)	
Microcalcifications									
Yes	2 (1.8)	22 (43.1)	<0.0001	1 (2)	23 (20.7)	0.0023	0 (0)	24 (15.8)	0.6072
No	107 (98.2)	29 (56.9)		48 (98)	88 (79.3)		8 (100)	128 (84.2)	

In the present study, the number of CDIS diagnoses was 10.6%, and the frequency of IDC diagnoses was 81.3%, close to those found in other Brazilian studies, which confirms the high number of late diagnoses of this disease<sup>19</sup>.

In our study, it was confirmed that breast density suffers modifications due to age, with a gradual replacement of fibroglandular tissue with adipose tissue. Women with liposubstituted breasts had the highest mean age, and women with dense breasts had the lowest mean age. This fact has also been proven in previous analyzes<sup>20</sup>.

As described in the literature, the extent of mammary neoplasm to the skin may lead to the appearance of secondary mammographic findings (skin retraction and thickening, and nipple retraction), related to high suspicion of malignancy<sup>21</sup>. In the present study, there was low prevalence of secondary mammographic

findings among women with breast cancer, showing that the insufficiency of these findings should not be interpreted as an absence of tumor malignancy<sup>21</sup>.

In this study, only 23.1% (n=37) of the 160 women with breast cancer were diagnosed in the infraclinical stage of the disease, through mammographic screening, indicating the need to increase the access to this diagnostic method.

Our data show that 76.5% of the CDIS cases were asymptomatic, and only 16.2% of the IDC cases were asymptomatic, revealing the greater difficulty in diagnosing the first, in accordance with the literature<sup>22</sup>. Research indicates that approximately 75 to 95% of CDIS cases are currently diagnosed in asymptomatic women because of the finding of calcifications in mammography, showing the importance of this test in the early diagnosis of breast cancer<sup>22</sup>.

Regarding the mammographic lesions analyzed, there was predominance of MCs in asymptomatic patients and an expressive number of nodules in those that presented clinical signs and symptoms, confirming the results found by other authors<sup>23,24</sup>.

Among the symptomatic women, the order of prevalence of clinical signs of breast cancer pointed out by our research corresponded to palpable nodule, skin alterations and papillary discharge, similarly to the information presented by other authors<sup>25,26</sup>. In our study, we also found strong association between skin changes at the clinical examination and the presence of a nodule on mammography, but this did not occur with papillary discharge, which did not present a significant association with the mammographic findings.

In relation to the most important mammographic characteristics for nodule malignancy, spiculated margins and irregular shape stood out, as shown in the data in the literature<sup>27</sup>.

With respect to MCs, a greater association of malignancy was observed in the presence of pleomorphic and grouped MCs, whereas amorphous MCs presented low probability of malignancy. Such information was in accordance with results found by other authors<sup>28-30</sup>.

In conclusion, the present study showed there was a prevalence of symptomatic women, with mammographic presentation of spiculated nodules and histological type of IDC. In the patients with lesions detected in the screening test, the pleomorphic and grouped MCs prevailed as the main finding of the CDIS.

Diagnostic mammography was the main form of breast cancer detection. This suggests that the late detection of malignant lesions may be related with the lack of access of these women to the screening tests or to the early mammographic detection of these lesions, revealing the need to improve control actions and care protocols of these patients.

**Table 2.** Association between mammographic presentation of the nodule and histological presentation of breast cancer.

Variables	IDC	CDIS	Other	P-value
	n (%)	n (%)	n (%)	
Nodule	113 (86.9)	6 (35.3)	10 (76.9)	<0.0001
Morphology of the nodule				
Round	16 (14.2)	1 (16.7)	3 (30)	0.2635
Oval	14 (12.4)	0 (0)	2 (20)	
Irregular	71 (62.8)	5 (83.3)	3 (30)	
Macrolobulated	12 (10.6)	0 (0)	2 (20)	
Nodule margin				
Spiculated	89 (78.8)	4 (66.7)	3 (30)	0.0029
Poorly defined	16 (14.2)	1 (16.7)	4 (40)	
Microlobulated	5 (4.4)	1 (16.7)	0 (0)	
Well defined	3 (2.6)	0 (0)	3 (30)	

IDC: invasive ductal carcinoma; DCIS: ductal carcinoma *in situ*.

**Table 3.** Association between mammographic presentation of microcalcifications and histological presentation of breast cancer.

Variables	IDC	CDIS	Other	P-value
	n (%)	n (%)	n (%)	
Microcalcifications	10 (7.7)	11 (64.7)	3 (23)	<0.0001
Morphology of microcalcifications				
Pleomorphic	8 (80)	7 (63.6)	1 (33.3)	0.3620
Amorphous	2 (20)	4 (36.4)	2 (66.7)	
Distribution of microcalcifications				
Grouping	6 (60)	4 (36.4)	3 (100)	<0.0001
Linear	1 (10)	1 (9)	0 (0)	
Segmental	2 (20)	3 (27.3)	0 (0)	
Branched	1 (10)	3 (27.3)	0 (0)	

IDC: invasive ductal carcinoma; DCIS: ductal carcinoma *in situ*.

## ACKNOWLEDGMENTS

We thank the Conselho Nacional de Desenvolvimento Científico e Tecnológico (CNPq), which fostered this scientific research, through the Institutional Scientific Initiation Scholarship

Program (PIBIC). We also thank the support provided by the Women's Hospital Prof. Dr. José Aristodemo Pinotti, Unicamp, for providing its infrastructure and qualified professionals to carry out this research.

## REFERENCES

1. Fitzmaurice C, Dicker D, Pain A, Hamavid H, Moradi-Lakeh M, MacIntyre MF, et al. The Global Burden of Cancer 2013. *JAMA Oncol.* 2015;1(4):505-27.
2. Curado MP, Edwards B, Shin HR, Ferlay J, Heanue M, Boyle P, et al. Cancer incidence in five continents, Vol. IX [IARC Scientific Publications, 160]. Lyon: IARC; 2007.
3. Brasil. Ministério da Saúde. Instituto Nacional do Câncer. Estimativa 2016. [cited 2016 mês 06]. Available from: <http://www.inca.gov.br/estimativa/2016/sintese-de-resultados-comentarios.asp>
4. Brasil. Ministério da Saúde. Instituto Nacional do Câncer. Documento de consenso. Brasil. 2004 [cited 2015 mês 04]. Available from: <http://www1.inca.gov.br/publicacoes/consensointegra.pdf>
5. Tabar L, Yen MF, Vitak B, Chen HHT, Smith RA, Duffy SW. Mammography service screening and mortality in breast cancer patients: 20-year follow-up before and after introduction of screening. *Lancet.* 2003;361(9367):1405-10.
6. Loberg M, Lousdal ML, Bretthauer M, Kalager M. Benefits and harms of mammography screening. *Breast Cancer Res.* 2015;17:63.
7. Jacksos VP. Screening mammography: controversies and headlines. *Radiology.* 2002;225(2):323-6.
8. Sinha R, Coyle C, Ring A. Breast cancer in older patients: national cancer registry data. *Int J Clin Pract.* 2013;67(7):698-700.
9. Gobbi H. Classificação dos tumores da mama: atualização baseada na nova classificação da Organização Mundial da Saúde de 2012. *J Bras Patol Med Lab.* 2012;48(6):463-74.
10. Eisenberg ALA, Koifman S. Aspectos gerais dos adenocarcinomas de mama, estadiamento e classificação histopatológica com descrição dos principais tipos. *Rev Bras Cancerol.* 2000;46(1):63-77.
11. Salles MA, Matias MARF, Resende LMP, Gobbi H. Variação inter-observador no diagnóstico histopatológico do carcinoma ductal *in situ* da mama. *Rev Bras Ginecol Obstet.* 2005;27(1):1-6.
12. Naseem M, Murray J, Hilton JF, Karamchandani J, Muradali D, Faragalla H, et al. Mammographic microcalcifications and breast cancer tumorigenesis: a radiologic-pathologic analysis. *BMC Cancer.* 2015;15:307.
13. Sickles EA, D'Orsi CJ, Bassett LW. ACR BI-RADS mammography. ACR BI-RADS Atlas, Breast Imaging Reporting and Data System. ACR BI-RADS Committee Ed., American College of Radiology, Reston, Virginia, 2013; 120-41.
14. Lakhani SR, Ellis IO, Schnitt SJ, Tan PH, Van de Vijver MJ. Classification of tumours of the breast. Lyon: IARC; 2012.
15. Nisen JA, Schwertman NC. A simple method of computing the sample size for Chi-square test for the equality of multinomial distributions. *Comput Stat Data An.* 2008;52(11):4903-8.
16. Macchetti AH. Estadiamento do câncer de mama diagnosticado no sistema público de saúde de São Carlos. *Med (Ribeirão Preto).* 2007;40(3):394-402.
17. Gonzaga CM, Freitas-Junior R, Curado MP, Sousa ALL, Souza-Neto JA, Souza MR. Temporal trends in female breast cancer mortality in Brazil and correlations with social inequalities: ecological time-series study. *BMC Public Health.* 2015;15(1):96.
18. Urban LABD, Duarte LD, Santos RD, Canella EO, Schaefer MB, Ferreira CAP, et al. Breast cancer imaging screening. *Radiol Bras.* 2012;45(6):334-9.
19. Abreu E, Koifman S. Fatores prognósticos no câncer da mama feminina. *Rev Bras Cancerol.* 2002;48:113-31.
20. Haiman CA, Hankinson SE, De Vivo I, Guillemette C, Ishibe N, Hunter DJ, et al. Polymorphisms in steroid hormone pathway genes and mammographic density. *Breast Cancer Res Treat.* 2003;77:27-36.
21. Veronesi U, Luini A, Costa A, Andreoli C. Mastologia oncológica. Milão: Medsi; 2002.
22. Alberto DV, Edson M. Calcificações malignas da mama – correlação mamografia – anatomia patológica. *Radiol Bras.* 2002;35(3):131-7.
23. Kemp C, Baracat FF, Rostagno R. Lesões não palpáveis da mama: diagnóstico e tratamento. Rio de Janeiro: Revinter; 2003.
24. Karamouzian MV, Likaki-Karatzas E, Ravazoula P, Badra FA, Koukouras D, Tzorakoleftherakis E, et al. Non-palpable breast carcinomas: correlation of mammographically detected malignant-appearing microcalcifications and molecular prognostic factors. *Int J Cancer.* 2002;102(1):86-90.
25. Walker S, Hyde C, Hamilton W. Risk of breast cancer in symptomatic women in primary care: a case-control study using electronic records. *Br J Gen Pract.* 2014;64(629):e788-93.
26. Mantroni I, Santini D, Zucchini G, Fiacchi M, Zanotti S, Ugolini G, et al. Nipple discharge: is its significance as a risk factor for breast cancer fully understood? *Breast Cancer Res Treat.* 2010;123(3):895-900.
27. Berg WA, Campassi C, Langenberg P, Sexton MJ. Breast Imaging Reporting and Data System: inter-and intraobserver variability in feature analysis and final assessment. *Am J Roentgenol.* 2000;174(6):1769-77.
28. Kim KI, Lee KH, Kim TR, Chun YS, Lee TH, Choi HY, et al. Changing patterns of microcalcification on screening mammography for prediction of breast cancer. *Breast Cancer.* 2015.
29. Tse GM, Tan PH, Cheung HS, Chu WCW, Lam WWM. Intermediate to highly suspicious calcification in breast lesions: a radiopathologic correlation. *Breast Cancer Res Treat.* 2008;110:1-7.
30. Cosar ZS, Çetin M, Tepe TK, Çetin R, Zarali AC. Concordance of mammographic classifications of microcalcifications in breast cancer diagnosis. Utility of the Breast Imaging Reporting and Data System (fourth edition). *Clin Imag.* 2005;29(6):389-95.